


An  
American  
Musical

Singapore

A  
Musical



# History

- 64-year-old Caucasian man with no past medical history went to the swimming pool for a break after a jog around the running track.

# Story from the Rescuer

Mr Seng Chiau Teck

# AED



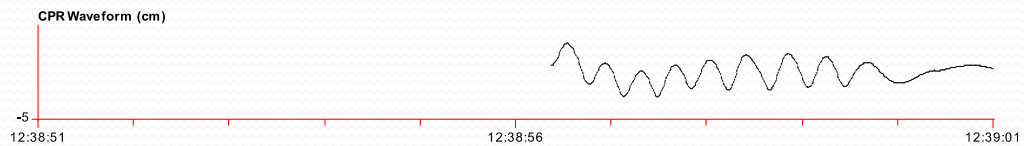# Resuscitator



# AED Recording



AED 12:38hr  
First Shock 12:39hr



rompt: press flashing shock button

2<sup>nd</sup> Shock 12:41hr

don't touch patient



ROSC 12:42hr

ECG x1






2:42:31

12:42:36

12:42:41

# Progress

- Paramedics arrived after 11 mins. GCS 3/15, initial rhythm sinus with good BP.
- Arrived at ED 13:20hr- BP 121/56, HR 78/min
- Started on Hypothermia protocol
- CT Brain normal, loaded with Dual Antiplatelet Therapy, sent for cardiac catheterization

- 
- Cardiac Catheterization- diagonal branch D1 LAD 95% stenosis- stented
  - Regained consciousness day 2, had retrograde amnesia. MRI/MRA brain normal, memory returned.
  - Echo and MRI showed asymmetrical hypertrophic cardiomyopathy, no LVOT obstruction. Focal myocardial fibrosis. AICD inserted
  - Went back to Hawaii well.

# Story from the Survivor

One year later...